

Cyst of Moll

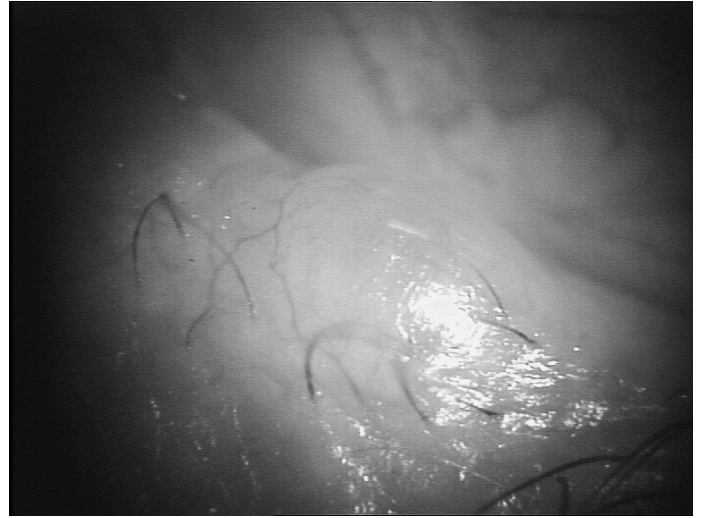
This is a cyst that appears on the lid margin. It often looks translucent because it is filled with clear serous fluid.

They are not cancerous in any way, just a fluid containing cyst. They arise from the Glands of Moll for reasons that no one knows. Their natural history is for them to slowly increase in size.

Thus they do not need to be removed unless they are causing irritation or cosmetic issues.

Treatment

It is tempting to pop them with a needle, but this simply collapses the cyst by draining the fluid but the cyst will reform. It is necessary to remove the cyst completely. This is best done as a minor operation procedure but is often done under the microscope in the operating theater. This is because the key to prevention of recurrence is to remove the cyst wall completely.



The procedure is undertaken under Local anesthesia and takes about 30 minutes.

Recurrences

This is unusual once the cyst has been removed, but does occasionally happen.

Nicholas Lee Esq FRCS FRCOphth 2011
Clinical Director Ophthalmology Department Hillingdon Hospital
Consultant Ophthalmologist Western Eye Hospital.